

THERAPEUTIC TARGETS OF ALPD AND CIRRHOSIS

Human umbilical cord mesenchymal stem cells improve liver function and ascites in decompensated liver cirrhosis patients

Zheng Zhang,* Hu Lin,* Ming Shi,* Ruonan Xu,* Junliang Fu, Jiyun Lv, Liming Chen, Sa Lv, Yuanyuan Li, Shuangjie Yu, Hua Geng, Lei Jin, George K K Lau and Fu-Sheng Wang

Research Center for Biological Therapy, The Institute of Translational Hepatology, Beijing 302 Hospital, Beijing, China



Fu-Sheng Wang

Key words

ascites, human, liver cirrhosis, stem cell, umbilical cord.

Accepted for publication 10 November 2011.

Abstract

Decompensated liver cirrhosis (LC), a life-threatening complication of chronic liver disease, is one of the major indications for liver transplantation. Recently, mesenchymal stem cell (MSC) transfusion has been shown to lead to the regression of liver fibrosis in mice and humans. This study examined the safety and efficacy of umbilical cord-derived MSC (UC-MSC) in patients with decompensated LC. A total of 45 chronic hepatitis B patients with decompensated LC, including 30 patients receiving UC-MSC transfusion, and 15 patients receiving saline as the control, were recruited; clinical parameters were detected during a 1-year follow-up period. No significant side-effects and complications were observed in either group. There was a significant reduction in the volume of ascites in patients treated with UC-MSC transfusion compared with controls ($P < 0.05$). UC-MSC therapy also significantly improved liver function, as indicated by the increase of serum albumin levels, decrease in total serum bilirubin levels, and decrease in the sodium model for end-stage liver disease scores. UC-MSC transfusion is clinically safe and could improve liver function and reduce ascites in patients with decompensated LC. UC-MSC transfusion, therefore, might present a novel therapeutic approach for patients with decompensated LC.

Correspondence

Professor Fu-Sheng Wang, Research Center for Biological Therapy, The Institute of Translational Hepatology, Beijing 302 Hospital, 100 the Western 4th Ring Middle Road, Beijing 100039, China. Email: fswang@public.bta.net.cn

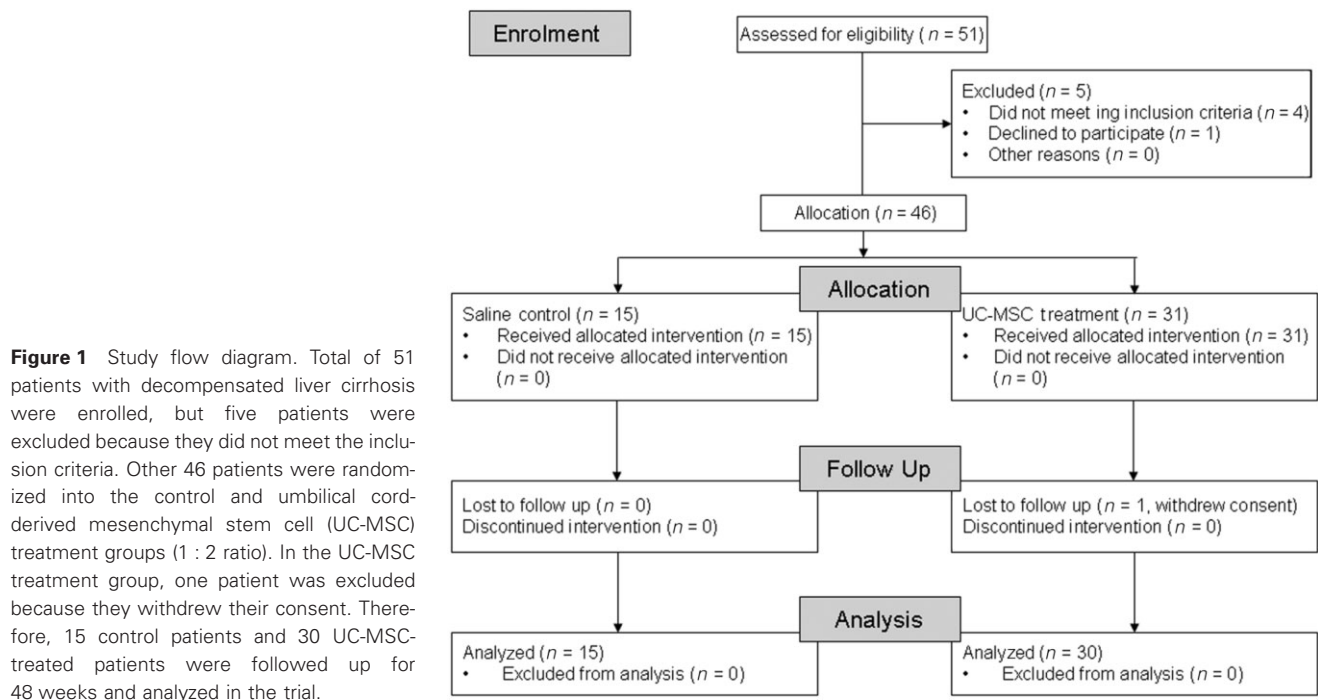
*These authors contributed equally to this work.

Introduction

Liver fibrosis is the major cause of morbidity and mortality in patients with chronic hepatitis B virus (HBV) infection.¹ Liver fibrosis can be reverted with the removal of the underlying etiology, such as control of HBV replication. However, if chronic inflammation and injury persist, liver fibrosis is likely to progress to liver cirrhosis (LC). LC is generally characterized by the formation and accumulation of an extracellular matrix, which lead to the progressive distortion of the hepatic architecture. Hepatic stellate cell (HSC) activation is usually considered a critical event in the pathogenesis of liver fibrosis.^{1,2} LC usually progresses irreversibly into a decompensated stage, which is characterized by a series of clinical manifestations, including ascites, variceal hemorrhage, and hepatic encephalopathy, while ascites is the most common clinical symptom in such patients.³ Although ascites might be treated with diuretics, periodic paracentesis, or a transjugular

intrahepatic portosystemic shunt, liver transplantation is the only option that can improve the survival of these patients. However, the severe shortage of donor livers, high costs, and potential serious complications have restricted the availability of liver transplantation worldwide. Therefore, alternative strategies are under intense investigation.

Mesenchymal stem cells (MSC), originating from the many mesenchymal and connective tissues,⁴ have self-renewal abilities and multidirectional differentiation potentials. They also interact with various types of immune cells, leading to immunomodulation.⁵ Recently, MSC have been used therapeutically in clinical trials for graft-versus-host disease,⁶ and appear to be effective in immune-mediated tissue injury, transplantation, and autoimmunity.⁷ In particular, MSC have also been used to treat liver diseases in animal models and patients. Studies from animal models have shown that bone marrow-derived MSC (BM-MSC) infusion ameliorates liver fibrosis^{8,9} and reverses fulminant hepatic failure.^{10,11}



In clinical trials, autologous BM-MSC infusion has been demonstrated to be safe and feasible, and can improve the liver function of some LC patients.^{12–14} However, in these studies, the small size of the patient cohorts and the lack of controls prevent firm conclusions being made with regard to the safety and efficacy of this treatment in liver diseases.¹⁵ In addition, BM-MSC from patients with chronic HBV infection suffer from proliferative deficiency, and might not be the best choice.¹⁶ In contrast, human umbilical cord-derived MSC (UC-MSC) are free from these limitations related to autologous BM-MSC. In addition, UC-MSC can be obtained from the discarded UC, and therefore, can be produced on a large scale. It has been reported that human UC-MSC infusion can improve liver fibrosis in rats.^{17,18} Therefore, UC-MSC have more potential to be used in clinical scenarios for the treatment of human liver diseases.

In our present study, we examine the safety and efficacy of UC-MSC transfusion in 30 decompensated LC patients with ascites and compare the patients to 15 matched controls who received saline infusion.

Methods

Patients

This open-labeled, paired, controlled study was registered at ClinicalTrials.gov of the National Institute of Health of the USA (registered no. NCT0120492). This study was authorized by the General Logistic Ministry of Health, China. After the approval of the project by the Ethics Committee of Beijing 302 Hospital, all patients signed a written, informed consent, in accordance to the Institutional Review Board guidelines for the protection of human patients. A total of 45 chronic hepatitis B patients with decompensated LC and ascites were assigned into either the treatment group

or the control group at a 2 : 1 ratio. In the treatment group, 30 patients were treated with UC-MSC transfusion, while in control group, 15 patients received saline infusion. Both groups of patients received conventional treatment (Fig. 1). The baseline clinical parameters were matched in the treatment and control groups (Table 1).

All patients had a history of chronic HBV infection, with ultrasonographic evidence of LC with ascites and/or portal hypertension, and/or low serum albumin (ALB) and/or high total bilirubin (TBIL), and/or a prolonged international normalized ratio (INR). The exclusion criteria were as follows: a history of moderate to severe hepatic encephalopathy, variceal bleeding, recent infection and/or ascites ultrafiltration, and/or dialysis during the previous 2 months before enrolment; the presence of severe comorbidities; the presence of any underlying neoplasm; evidence of extrahepatic biliary diseases; the presence of hepatic, portal, or splenic vein thromboses on Doppler ultrasonography; active substance abuse; the lack of a supportive family; and if the patients were unwilling to sign the informed consent form.

Preparation and identification of UC-MSC

With the written consent of the parents, fresh human UC were collected. UC-MSC were prepared according to a previous study.¹⁹ In brief, the UC vessels were removed, and the mesenchymal tissue was diced into cubes, washed, and finally seeded into a T75-cm² tissue culture flask. After 12–15 days of culture, the remnants of the cord fragments were removed, and the adherent cells were cultured until they were confluent (first passage). These UC-MSC were then cultured and collected between the third and fourth passages for transfusion into patients.

Before transfusion, the UC-MSC were subjected to quality control. The UC-MSC were digested and stained with anti-CD31-

Table 1 Baseline demographic and clinical data of enrolled patients

| | Control | Umbilical cord-derived mesenchymal stem cells | <i>P</i> -values |
|---------------------------------|---|---|------------------|
| <i>n</i> | 15 | 30 | ND |
| Sex (male/female) | 14/1 | 26/4 | 0.881 |
| Age (years) | 47 (29–64) | 48 (25–64) | 0.914 |
| Ascites (mm) | 66 (10–86) | 57 (20–104) | 0.682 |
| Alanine aminotransferase (IU/L) | 40 (14–119) | 37 (17–101) | 0.562 |
| Serum albumin (g/L) | 28.0 (21–34) | 28.5 (19–38) | 0.682 |
| Total bilirubin (μmol/L) | 44.0 (6.5–115.6) | 37.1 (21.2–120.2) | 0.555 |
| Prothrombin activity (%) | 65 (39–92) | 59 (26–81) | 0.268 |
| International normalized ratio | 1.27 (1.07–1.47) | 1.36 (1.10–2.27) | 0.262 |
| Creatinine (μmol/L) | 73 (60–204) | 75 (56–158) | 0.673 |
| Cholinesterase (U/L) | 2165 (1252–5222) | 2029 (672–3906) | 0.455 |
| Median serum HBV levels (IU/mL) | 7.9×10^5 (< 100 – 1.7×10^8) | 3.8×10^5 (< 100 – 1.3×10^7) | 0.343 |
| HBeAg positive/negative | 6/9 | 14/16 | 0.881 |

Data are shown as the median and range. HBeAg, Hepatitis B e antigen; HBV, hepatitis B virus; ND, no data.

fluorescein isothiocyanate (FITC), anti-CD34–FITC, anti-CD105–FITC, anti-CD45–FITC, anti-CD90–PE (phycoerythrin), anti-CD29–PE, anti-CD44–PE, anti-CD73–PE, and anti-HLA (human leukocyte antigen)–DR–PE (Becton Dickinson, Franklin Lakes, NJ, USA) or the isotype monoclonal antibody (mAb). The cells were collected using FACSCalibur (Becton Dickinson, San Jose, CA, USA); the data were analyzed by FlowJo software (TreeStar, Ashland, OR, USA). Alternatively, the digested cells were cultured under conditioned medium (Stem Cell Tech, Vancouver, BC, Canada), and were subsequently assessed by alkaline phosphatase staining and Oil Red O staining, respectively. Moreover, bacteriological tests were performed at every passage and prior to injection.

UC-MSc transfusion

By the fourth passage, the cells were suspended at a concentration of 0.5×10^6 /kg body weight in saline, and were slowly infused intravenously. The control patients received the same volume of saline. Each patient received UC-MSc or saline treatment once every 4 weeks three times, and were then followed up for an additional 40 weeks (Fig. S1).

Follow up and outcome measures

The following tests were performed at weeks 0, 1, 2, 4, 8, 12, 24, 36, and 48: liver function tests: serum TBIL, ALB, and cholinesterase (CHE); renal function markers: urea, uric acid, and creatinine (CRE); thrombin marker prothrombin activity (PTA) and INR; and white blood cell count (WBC), hemoglobin, and platelet counts. The volume of hypogastric ascites was detected on ultrasonography, and the model for end-stage liver disease (MELD) Na scores were used to evaluate prognosis. History taking and physical examinations were also performed at each clinical visit. The presence of fever, peripheral edema, rash, nausea, and vomiting were recorded in details at each visit.

ELISA

The serum laminin, hyaluronic acid, procollagen type III N-terminal peptide (PIIINP), and collagen type IV were detected

using a chemiluminescence quantitative immunoassay, and hepatic growth factor (HGF) and transforming growth factor-β (TGF-β) were detected using ELISA. The cut-off value was 10 pg/mL.

Statistical analysis

All data were analyzed using SPSS 13.0 for Windows software (SPSS, Chicago, IL, USA). Multiple comparisons were made among the different groups using the Kruskal–Wallis test for non-parametric data. Comparisons between various individuals were performed using the Mann–Whitney *U*-test; comparisons between parameters in the same individual were performed using the Wilcoxon matched pairs *t*-test. Actuarial overall disappearance rates of ascites were measured from the onset of treatment to the 48-week review, and were analyzed by the Kaplan–Meier method. The log–rank test was applied to compare between the groups. The plots were performed using one minus survival model. For all tests, two-sided *P* < 0.05 was considered to be significant.

Results

Characterization of UC-MSc

UC-MSc were fusiform on the flask, with the potential for either osteogenic and adipogenic differentiation (Fig. S2a). These cells express high levels of CD29, CD73, CD90, CD105, and CD44, but do not express CD31, HLA-DR, CD34, and CD45 (Fig. S2b), indicating that they contain no hematopoietic cells. These cells can produce high levels of HGF, interleukin (IL)-6, and granulocyte colony-stimulating factor (G-CSF), and moderate levels of TGF-β and IL-7, but low levels of IL-2, IL-10, and interferon-γ (Fig. S2c). Thus, the UC-MSc had similar characteristics to those previously reported in BM-MSc.¹⁹

Efficacy of UC-MSc transfusion *in vivo*

Liver function tests

We first found that ALB levels were significantly increased in both the UC-MSc and control groups after 1 week of treatment. Impor-

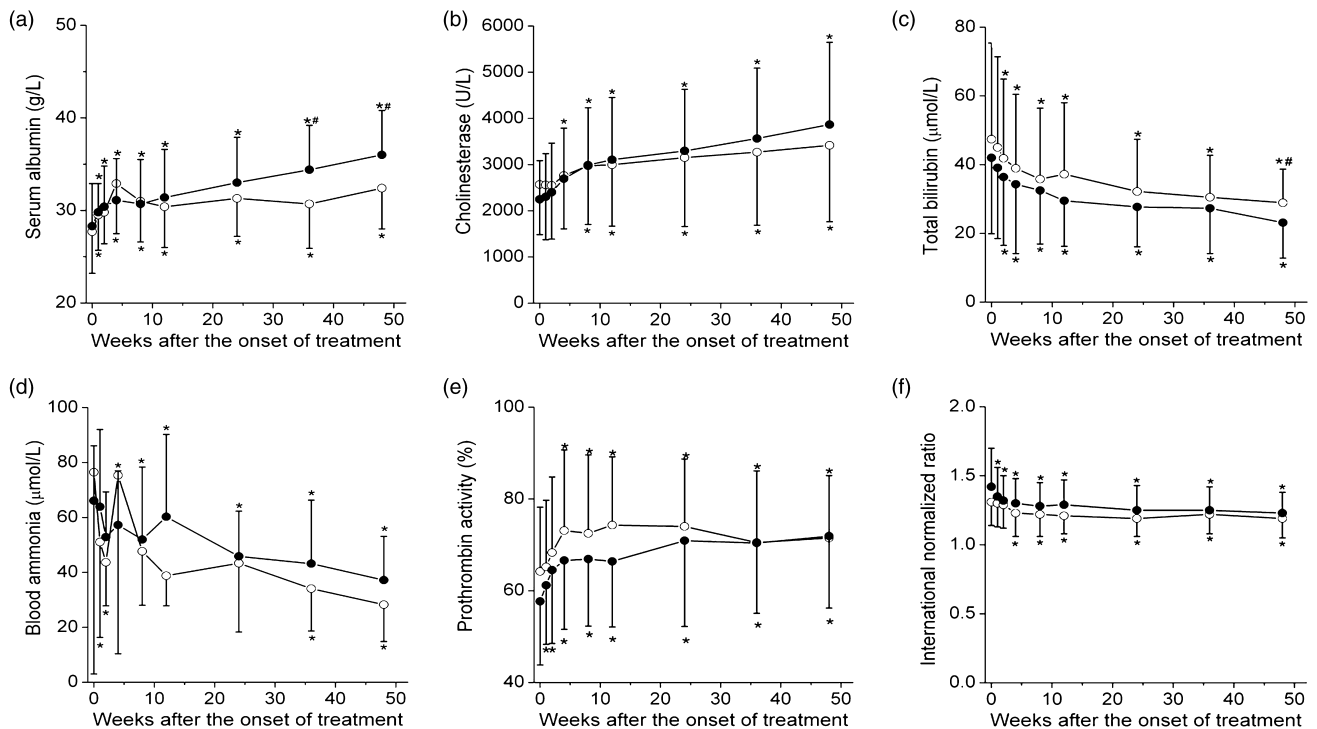


Figure 2 Influence of umbilical cord-derived mesenchymal stem cell (UC-MSC) therapy on liver functions in decompensated liver cirrhosis patients with ascites. Serum albumin (a), cholinesterase (b), total bilirubin (c), blood ammonia (d), prothrombin activity (e), and international normalized ratio (f) were used to reflect liver function. * $P < 0.05$ indicates a significant difference between the baseline value and the value at various time points after UC-MSC plus conventional therapy or conventional therapy. #, significant difference ($P < 0.05$) between control values and UC-MSC values at various time points. \circ —, control; \bullet —, UC-MSC.

tantly, ALB levels were significantly higher at weeks 36 and 48 in the UC-MSC group, compared to the controls ($P < 0.05$, Fig. 2a). We also found that serum CHE levels were significantly increased at week 4 of UC-MSC treatment, which occurred earlier than the control groups (at week 8). No significant differences in CHE levels were found between the control and UC-MSC treatment groups at any other time points (Fig. 2b).

UC-MSC transfusion also significantly decreased TBIL levels after week 2; in particular, at week 48, TBIL levels were significantly lower in the UC-MSC group than that in the control group (Fig. 2c). No significant differences in ammonia levels were found between the control and UC-MSC groups, although they were gradually decreased in both the control and UC-MSC groups after treatment (Fig. 2d). These data indicate that UC-MSC treatment has the potential to improve liver function in decompensated LC patients.

Thrombin function tests

PTA and INR values are usually used in the clinical setting as markers reflecting thrombin function of LC patients. We found that PTA was increased significantly in both the control and UC-MSC treatment groups (Fig. 2e), and INR levels were decreased accordingly (Fig. 2f). Interestingly, the improvement of thrombin function occurred at an earlier stage in UC-MSC-treated

patients than in control patients, suggesting that UC-MSC transfusion might improve thrombin function earlier in decompensated LC patients with ascites.

Renal function tests

We also monitored renal function parameters, such as urea, CRE, and uric acid during the treatment course (Fig. 3a–c). No significant alterations were observed in these markers during the follow-up period for both groups; however, the serum CRE levels were significantly decreased at week 8 in UC-MSC-treated patients (Fig. 3b).

MELD Na score

The MELD Na score has been demonstrated to be a better marker than the MELD score in the evaluation for the prognosis of end-stage liver diseases.^{20–22} We found that the MELD Na scores were simultaneously decreased in the control and UC-MSC treatment groups (Fig. 3d). In particular, the MELD Na scores were decreased earlier in the UC-MSC-treated patients than the control group. At week 48, the MELD Na score was significantly reduced in the UC-MSC treatment group compared to the control group.

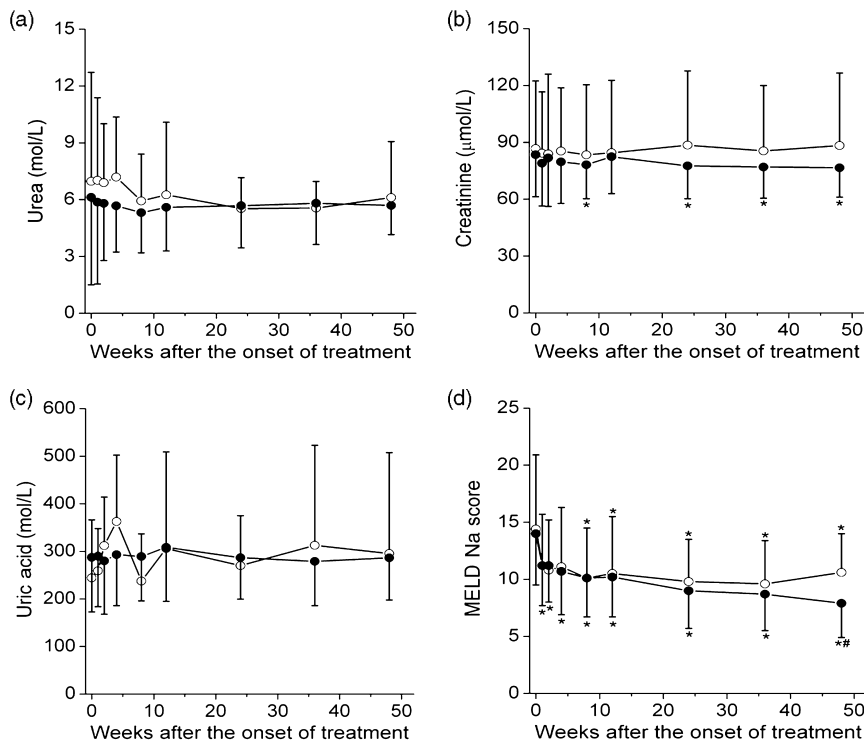


Figure 3 Influence of umbilical cord-derived mesenchymal stem cell (UC-MSC) therapy on renal function and model for end-stage liver disease (MELD) Na scores in decompensated liver cirrhosis patients with ascites. Serum renal function markers, urea (a), creatinine (b), and uric acid (c), were detected, and MELD Na (d) scores were analyzed during the period of treatment. * $P < 0.05$ indicates a significant difference between the baseline value and those at various time points after treatment. #, significant difference ($P < 0.05$) between saline control values and UC-MSC values at the appropriate time points. \circ —, control; \bullet —, UC-MSC.

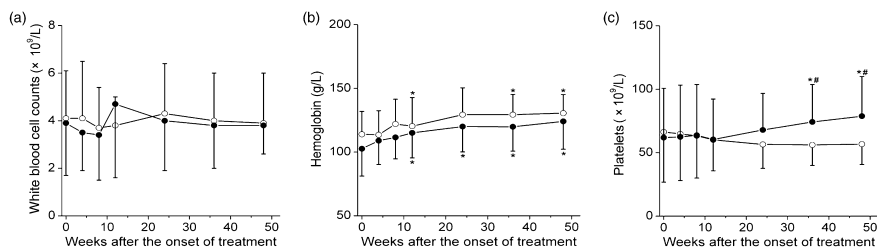


Figure 4 Impact of umbilical cord-derived mesenchymal stem cell (UC-MSC) therapy on the routine blood test in decompensated liver cirrhosis patients with ascites. White blood cell counts (a), hemoglobin (b), and platelet counts (c) were detected during the period of treatment. * $P < 0.05$ indicates a significant difference between the baseline value and that at various time points after treatment. #, significant difference ($P < 0.05$) between saline control values and UC-MSC values at the corresponding time points. \circ —, control; \bullet —, UC-MSC.

Routine blood tests

No significant changes were found in peripheral WBC in both the control and UC-MSC treatment groups (Fig. 4a). The hemoglobin levels were significantly increased after 12 weeks of treatment in both groups (Fig. 4b). Importantly, platelet counts were persistently increased after 36 weeks of UC-MSC treatment; in contrast, they were just maintained at low levels in the control group (Fig. 4c). Thus, at weeks 36 and 48, the platelet counts were significantly higher in UC-MSC-treated patients than those in the control group.

Ascites reduction

We further found that the hypogastric ascites volume by ultrasonography was significantly decreased in the UC-MSC treatment

group at weeks 1, 2, 12, 36, and 48 (Fig. 5a). We further found that the rate of ascites disappearance was significantly higher in the UC-MSC treatment group than that in the control group (log-rank test, with $P = 0.001$, Fig. 5b), suggesting that UC-MSC transfusions reduce ascites volume in decompensated LC patients.

Liver fibrosis markers

Serum laminin, hyaluronic acid, PIIINP, and type IV collagen are usually used to evaluate the disease severity of liver fibrosis in the clinical setting. In the present study, we found that the concentrations of these markers were significantly decreased at weeks 24 and 48 in the UC-MSC treatment group (Fig. 6). Interestingly, at weeks 24 and 48, reduction of the serum laminin concentration was significantly higher in the UC-MSC group than in the controls.

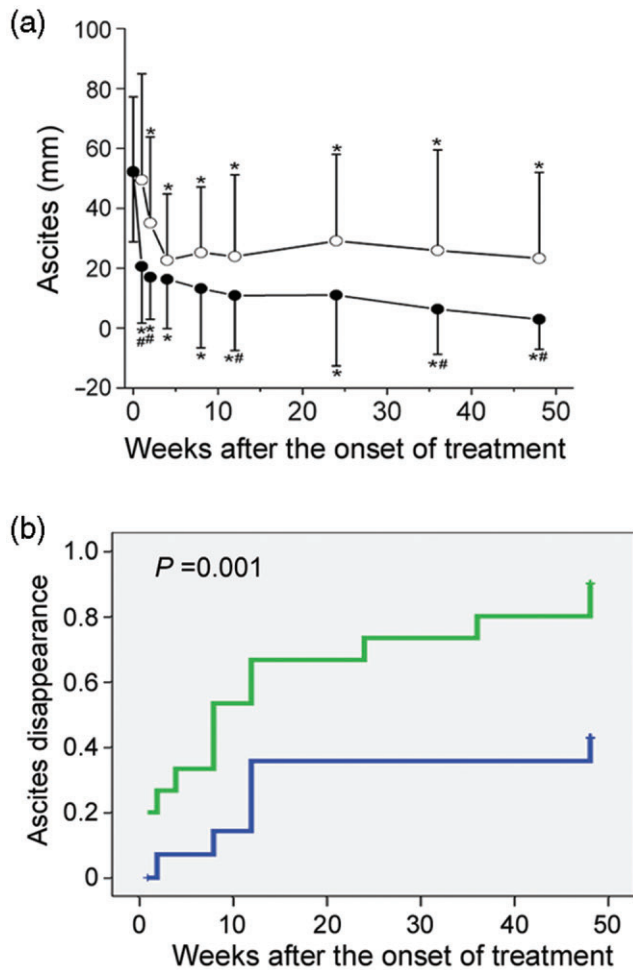


Figure 5 Umbilical cord-derived mesenchymal stem cell (UC-MSC) therapy improves ascites remission in decompensated liver cirrhosis with ascites. (a) Change in volume of ascites during the course of UC-MSC or control treatment. * $P < 0.05$ indicates a significant difference between the baseline value and that at various time points after UC-MSC or saline therapy. #, significant difference ($P < 0.05$) between saline control values and UC-MSC values at the corresponding time points. (b) Rate of ascites disappearance in the control and UC-MSC treatment groups at various time points. P -values that demonstrate statistically-significant differences between the control and UC-MSC groups are indicated. —, control; —, UC-MSC.

HGF attenuates, and TGF- β stimulates liver fibrosis.¹ We found that there was a significantly higher level of serum HGF at week 48 in the UC-MSC treatment group than in the control group (Fig. 6). No significant alteration was found in the levels of plasma TGF- β .

Safety of UC-MSC transfusion *in vivo*

Clinical symptoms and signs

In this study, four patients developed a self-limiting fever (37–38°C) within 2–6 h of UC-MSC transfusion, and recovered within

12 h, without any additional specific treatment. No short-term clinical adverse effects, including right upper quadrant pain, pruritus or skin rash, infection, coma, or shock, were reported in all the patients. We also found that lower limb edema disappearance occurred more quickly in the UC-MSC group (from 53.3% at onset, to 16.7% at week 4) than in the control group (maintained 26.7% from onset to week 4) (Table S1).

Complications

We examined the occurrence of complications throughout the trial (Table S2). No significant statistical differences were found in the occurrence of complications, including hepatocellular carcinoma, upper gastrointestinal hemorrhage, hepatic encephalopathy, and primary peritonitis between the UC-MSC treatment and control groups.

Serum HBV loads

There was no significant difference in the rate of reduction of serum HBV-DNA in the UC-MSC treatment and control groups (Table S3).

Discussion

The development of ascites is related to two main pathogenetic mechanisms in decompensated LC patients: portal hypertension and renal sodium retention.³ Recently, stem cell-based therapies have emerged as a novel alternative for the treatment of such patients.⁷ In particular, BM-MSC transfusion has been shown to be promising for the treatment of LC patients.^{12–14} However, UC-MSC treatment has not been used for the treatment of such patients.

This novel study indicated that UC-MSC infusion through the peripheral vein is safe and feasible in decompensated LC patients with ascites. No significant differences in the occurrences of short-term side-effect profiles and long-term complications were found between the UC-MSC treatment and control groups. Similar to previous reports with regards to BM-MSC transfusion,^{12–14} UC-MSC treatment ameliorated some of the clinical symptoms and signs, and is, therefore, able to be used in clinics.

More importantly, this study demonstrated some promising results in the efficacy of UC-MSC treatment in such patients. The most prominent efficacy is that UC-MSC can significantly reduce the hypogastric ascites volume and induce ascites remission. The relevant mechanisms remain obscure. One possibility is that UC-MSC treatment might exert antifibrotic effects, and subsequently relieve portal hypertension. In this respect, UC-MSC could decrease HSC activation via UC-MSC-derived IL-10 and tumor necrosis factor (TNF)- α ,^{23,24} or induce HSC apoptosis partially mediated by HGF.^{24,25} Indeed, UC-MSC transfusion decreased the levels of serum liver cirrhosis markers in the study. In addition, MSC might also overexpress matrix metalloproteinases (MMP), especially MMP-9, which have fibrolytic effects.²⁶ Thus, UC-MSC act through multiple mechanisms to coordinate a dynamic, integrated response to HSC activation, and reduce the resistance to portal flow at the sinusoidal level,³ finally leading to a greater degree of ascites remission. Our data also indicated that UC-MSC transfusion can partially decrease serum CRE, but not urea and uric acid levels, indicating that UC-MSC transfusion might improve renal

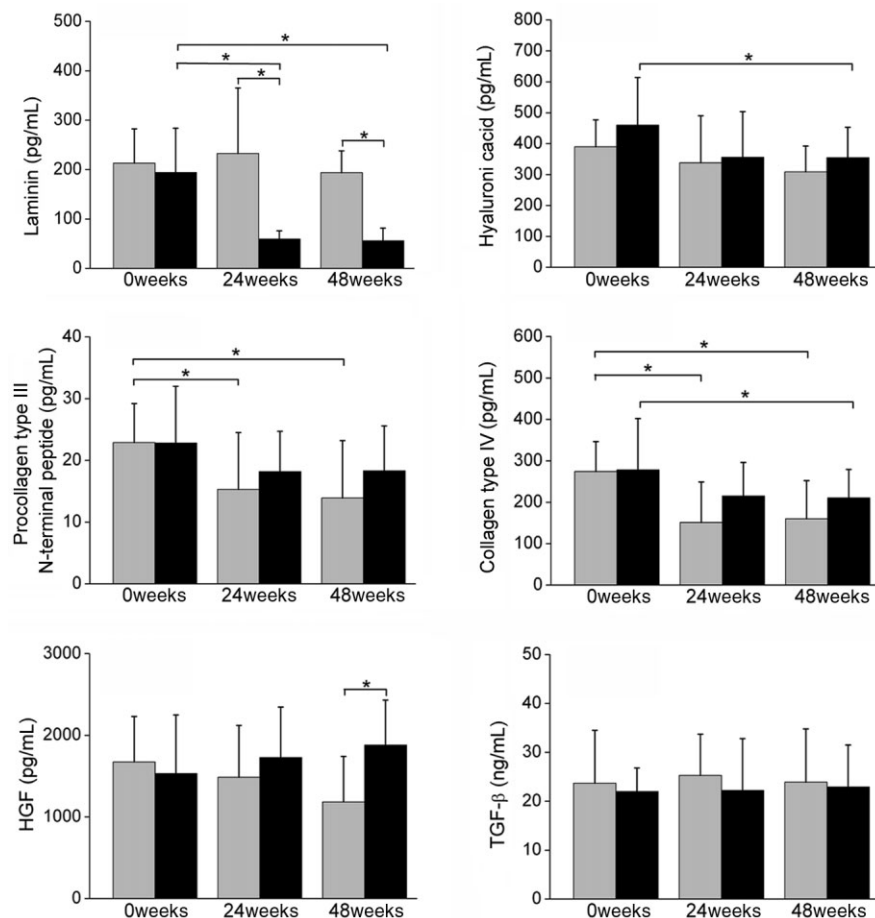


Figure 6 Changes of serum liver fibrosis markers and cytokines after umbilical cord-derived mesenchymal stem cell (UC-MSC) treatment of decompensated liver cirrhosis patients with ascites. Plasma laminin, hyaluronic acid, procollagen type III N-terminal peptide, and collagen type IV, as well as cytokines hepatic growth factor (HGF) and transforming growth factor- β (TGF- β) were detected using ELISA assays. * $P < 0.05$ indicates a significant difference between the two groups. , control; , UC-MSC.

function of decompensated LC patients. Further studies are required to confirm the decrease of sinusoidal portal hypertension and sodium retention by the kidney after UC-MSC transfusion.

We also showed that UC-MSC transfusion can improve liver function, as evidenced by an increase in serum ALB levels, a decrease in TBIL levels, and a reduction in blood lactic acid and prothrombin time activity earlier than the control treatment over the entire follow-up period. These findings, in combination with other reports,^{12–14} suggest that UC-MSC might improve the function of hepatocytes. However, MSC have the potential to differentiate into hepatocytes, both *in vitro* and *in vivo*.^{27,28} Alternatively, MSC might also increase residual hepatocyte proliferation by supplying growth factors and cytokines, such as HGF,²⁵ which are critical for the process of hepatic regeneration.^{23,25,29–31} Indeed, several reports have shown that MSC have the capacity to secrete various bioactive molecules,³² and exert a protective role for acute liver injury.^{10,33} Collectively, these studies support the therapeutic effect of UC-MSC on the improvement of liver functions, which might be due to cytokines that modulate the proliferation, viability, and function of resident hepatocytes.²⁹

Our study also found that UC-MSC transfusion could significantly reduce MELD Na in these patients. This is similar to previous studies in which the Child–Pugh score was employed to evaluate the effect of MSC on liver prognosis.^{12,13} Notably, the MELD Na score has recently been demonstrated to be a better prognostic marker for

liver disease, while the Child–Pugh score might be biased due to the interobserver variation in the clinical evaluation. Thus, different scoring systems used by clinicians might lead to various evaluation effects of UC-MSC therapy in LC patients.

Notably, the present study was conducted on larger groups in comparison to previous studies.^{12–14} This study is a 2:1-pair, controlled design; the control and treatment groups were homogeneous in the etiology of liver disease and their baseline clinical characteristics (Table 1). Therefore, this design, at least to some extent, provides more convincing data related to the safety and efficacy of UC-MSC in the treatment of decompensated LC. Several other limitations were also present in this study. First, we did not track the infused UC-MSC in patients *in vivo*, which is very important in order to understand the precise way that UC-MSC function. Second, we did not document the histological alterations in the studied patients, because liver biopsy carries a high risk in LC patients with ascites. However, the present study highlights several key issues that should be considered in future study designs, such as the optimal type of stem cells that will be infused, the minimum effective number of cells, and the optimal route of administration. Thus, our current findings demonstrate that UC-MSC transfusion via the peripheral vein is safe and has some promising results in the improvement of liver function and the remission of ascites in decompensated LC patients with ascites. Future larger-scale, randomized, double-blinded, placebo

designs should be conducted to confirm the use of UC-MSC treatment in such patients.

Acknowledgment

We greatly appreciate Dr Bin Gao (National Institute on Alcohol Abuse and Alcoholism/National Institute of Health) for critical reading of the manuscript.

References

- Hernandez-Gea V, Friedman SL. Pathogenesis of liver fibrosis. *Annu. Rev. Pathol.* 2011; **6**: 425–56.
- Moreira RK. Hepatic stellate cells and liver fibrosis. *Arch. Pathol. Lab. Med.* 2007; **131**: 1728–34.
- Salerno F, Guevara M, Bernardi M *et al.* Refractory ascites: pathogenesis, definition and therapy of a severe complication in patients with cirrhosis. *Liver Int.* 2010; **30**: 937–47.
- Jiang Y, Jahagirdar BN, Reinhardt RL *et al.* Pluripotency of mesenchymal stem cells derived from adult marrow. *Nature* 2002; **418**: 41–9.
- Uccelli A, Moretta L, Pistoia V. Mesenchymal stem cells in health and disease. *Nat. Rev. Immunol.* 2008; **8**: 726–36.
- Le Blanc K, Frassoni F, Ball L *et al.* Mesenchymal stem cells for treatment of steroid-resistant, severe, acute graft-versus-host disease: a phase II study. *Lancet* 2008; **371**: 1579–86.
- Singer NG, Caplan AI. Mesenchymal stem cells: mechanisms of inflammation. *Annu. Rev. Pathol.* 2011; **6**: 457–78.
- Rabani V, Shahsavani M, Gharavi M, Piryaei A, Azhdari Z, Baharvand H. Mesenchymal stem cell infusion therapy in a carbon tetrachloride-induced liver fibrosis model affects matrix metalloproteinase expression. *Cell Biol. Int.* 2010; **34**: 601–5.
- Chang YJ, Liu JW, Lin PC *et al.* Mesenchymal stem cells facilitate recovery from chemically induced liver damage and decrease liver fibrosis. *Life Sci.* 2009; **85**: 517–25.
- Parekkadan B, van Poll D, Suganuma K *et al.* Mesenchymal stem cell-derived molecules reverse fulminant hepatic failure. *PLoS ONE* 2007; **2**: e941.
- Kuo TK, Hung SP, Chuang CH *et al.* Stem cell therapy for liver disease: parameters governing the success of using bone marrow mesenchymal stem cells. *Gastroenterology* 2008; **134**: 2111–21.
- Terai S, Ishikawa T, Omori K *et al.* Improved liver function in patients with liver cirrhosis after autologous bone marrow cell infusion therapy. *Stem Cells* 2006; **24**: 2292–8.
- Mohamadnejad M, Alimoghaddam K, Mohyeddin-Bonab M *et al.* Phase I trial of autologous bone marrow mesenchymal stem cell transplantation in patients with decompensated liver cirrhosis. *Arch. Iran. Med.* 2007; **10**: 459–66.
- Kharaziha P, Hellstrom PM, Noorinayer B *et al.* Improvement of liver function in liver cirrhosis patients after autologous mesenchymal stem cell injection: a phase I–II clinical trial. *Eur. J. Gastroenterol. Hepatol.* 2009; **21**: 1199–205.
- Lorenzini S, Andreone P. Stem cell therapy for human liver cirrhosis: a cautious analysis of the results. *Stem Cells* 2007; **25**: 2383–4.
- Zhong YS, Lin N, Deng MH, Zhang FC, Tang ZF, Xu RY. Deficient proliferation of bone marrow-derived mesenchymal stem cells in patients with chronic hepatitis B viral infections and cirrhosis of the liver. *Dig. Dis. Sci.* 2010; **55**: 438–45.
- Jung KH, Shin HP, Lee S *et al.* Effect of human umbilical cord blood-derived mesenchymal stem cells in a cirrhotic rat model. *Liver Int.* 2009; **29**: 898–909.
- Tsai PC, Fu TW, Chen YMA *et al.* The therapeutic potential of human umbilical mesenchymal stem cells from Wharton's Jelly in the treatment of rat liver fibrosis. *Liver Transpl.* 2009; **15**: 484–95.
- Lu LL, Liu YJ, Yang SG *et al.* Isolation and characterization of human umbilical cord mesenchymal stem cells with hematopoiesis-supportive function and other potentials. *Haematologica* 2006; **91**: 1017–26.
- Biggins SW, Kim WR, Terrault NA *et al.* Evidence-based incorporation of serum sodium concentration into MELD. *Gastroenterology* 2006; **130**: 1652–60.
- Samuel D. MELD-Na as a prognostic score for cirrhotic patients: hyponatremia and ascites are back in the game. *J. Hepatol.* 2009; **50**: 836–8.
- Kim WR, Biggins SW, Kremers WK *et al.* Hyponatremia and mortality among patients on the liver-transplant waiting list. *N. Engl. J. Med.* 2008; **359**: 1018–26.
- Wang J, Bian C, Liao L *et al.* Inhibition of hepatic stellate cells proliferation by mesenchymal stem cells and the possible mechanisms. *Hepatol. Res.* 2009; **39**: 1219–28.
- Parekkadan B, van Poll D, Megeed Z *et al.* Immunomodulation of activated hepatic stellate cells by mesenchymal stem cells. *Biochem. Biophys. Res. Commun.* 2007; **363**: 247–52.
- Yu Y, Lu L, Qian X *et al.* Antifibrotic effect of hepatocyte growth factor-expressing mesenchymal stem cells in small-for-size liver transplant rats. *Stem Cells Dev.* 2010; **19**: 903–14.
- Lee MJ, Jung J, Na KH *et al.* Anti-fibrotic effect of chorionic plate-derived mesenchymal stem cells isolated from human placenta in a rat model of CCl₄-injured liver: potential application to the treatment of hepatic diseases. *J. Cell. Biochem.* 2010; **111**: 1453–63.
- Hong SH, Gang EJ, Jeong JA *et al.* *In vitro* differentiation of human umbilical cord blood-derived mesenchymal stem cells into hepatocyte-like cells. *Biochem. Biophys. Res. Commun.* 2005; **330**: 1153–61.
- Aurich I, Mueller LP, Aurich H *et al.* Functional integration of hepatocytes derived from human mesenchymal stem cells into mouse livers. *Gut* 2007; **56**: 405–15.
- Wang Y, Yao HL, Cui CB *et al.* Paracrine signals from mesenchymal cell populations govern the expansion and differentiation of human hepatic stem cells to adult liver fates. *Hepatology* 2010; **52**: 1443–54.
- Lin N, Tang Z, Deng M *et al.* Hedgehog-mediated paracrine interaction between hepatic stellate cells and marrow-derived mesenchymal stem cells. *Biochem. Biophys. Res. Commun.* 2008; **372**: 260–5.
- Deng X, Chen YX, Zhang X *et al.* Hepatic stellate cells modulate the differentiation of bone marrow mesenchymal stem cells into hepatocyte-like cells. *J. Cell. Physiol.* 2008; **217**: 138–44.
- Kallis YN, Alison MR, Forbes SJ. Bone marrow stem cells and liver disease. *Gut* 2007; **56**: 716–24.
- Taniguchi E, Kin M, Torimura T *et al.* Endothelial progenitor cell transplantation improves the survival following liver injury in mice. *Gastroenterology* 2006; **130**: 521–31.

Supporting information

Additional supporting information may be found in the online version of this article:

Figure S1 Study protocols.

Figure S2 Identification of umbilical cord-derived mesenchymal stem cells (UC-MSC). (a) Shape of cells and the adipogenic (positive Oil Red O staining) and osteogenic (positive alkaline phosphatase staining) differentiation of UC-MSC (×200). (b) Representative histogram depicting the expression patterns of

UC-MSc surface markers, including CD29, CD73, CD90, CD105, CD44, CD31, human leukocyte antigen (HLA)-DR, and CD34. Values represent the percentages of UC-MSc that expressed these surface markers. (c) Cytokine profiles produced by UC-MSc. Total of five clones from various UC were characterized.

Table S1 Proportion of patients with double leg edema.

Table S2 Complications between the control and umbilical cord-derived mesenchymal stem cell treatment groups at the end of study.

Table S3 Proportion of patients with serum hepatitis B virus loads below the detection limit.

Please note: Wiley-Blackwell are not responsible for the content or functionality of any supporting materials supplied by the authors. Any queries (other than missing material) should be directed to the corresponding author of the article.